




Primärtandskaries - Best practice


Maria Lundmark

ST-tandläkare | Pedodonti
 Avdelningen för barn- och ungdomsvård
 Institutionen för odontologi | Karolinska Institutet



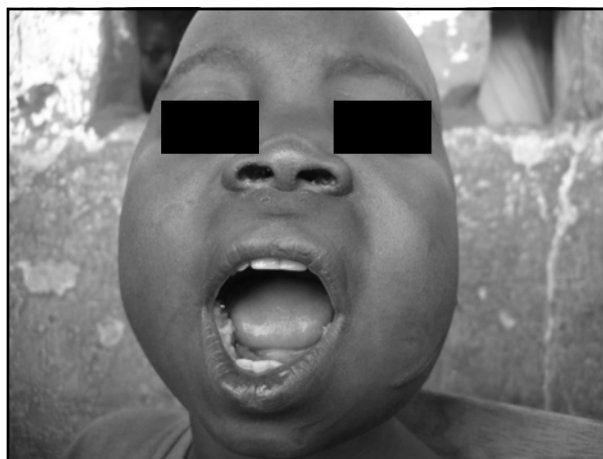Agenda

- Kariesstatus
- Behandlingsalternativ
- Patientfall




Primärtandskaries

"Låt den första kariesskadan bli den sista"







Syftet

- Vad säger forskningen?
- Evidens
- Vilka behandlingar rekommenderar vi?



21 november 2018 5



Vilka behandlingar ska vi gå igenom?


Behandlingar
Tidig bukkal/approximal emaljkarier
Buckal/approximal dentinkaries incisiver
Buckal dentinkaries molarer
Ocklusal emaljkarier
Ocklusal dentinkaries
Approximal emaljkarier
Approximal dentinkaries
PCL i primära molarer
Pulpanekros i primär tand

 Karolinska Institutet

Valet av behandling?

- Vem är patienten?
- Hur gammal?
- Kooperation
- Omfattning

21 november 2018 7

 Karolinska Institutet

Förutsättningar


Behandlingssituation

Lokalbedövning

Premedicinering
-> N2O
-> Midazolam

Narkos


21 november 2018 7

 Karolinska Institutet

Urvalet

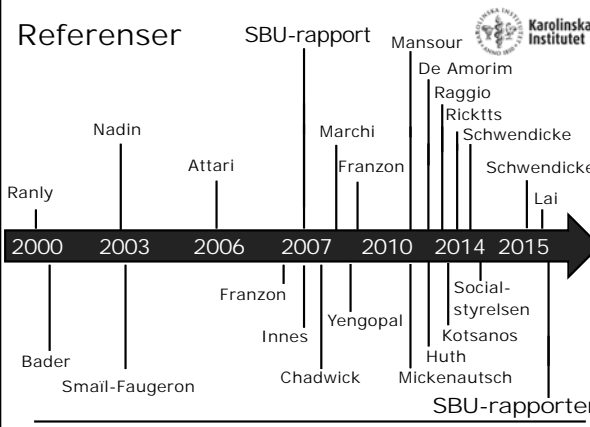
- SBU-rapporten
- Systematiska meta-analyser
- Vetenskapliga artiklar

21 november 2018 9

 Karolinska Institutet

Referenser


SBU-rapport



2000 2003 2006 2007 2010 2014 2015

SBU-rapporten

21 november 2018 9

 Karolinska Institutet

SBU-rapporten

Kunskapslucka

← ?

Mejäre et al. 2015 11

 Karolinska Institutet

SBU-rapporten


Översikt

Kunskapslucka

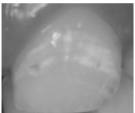
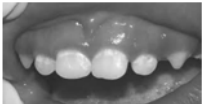
Stimulera till mer klinisk forskning

Mejäre et al. 2015 21 november 2018 12

Behandlingar



- Tidig buckal emaljkarier
- Buckal dentinkaries incisiver
- Buckal dentinkaries molarer
- Ocklusal emaljkarier
- Ocklusal dentinkaries
- Approximal emaljkarier
- Approximal dentinkaries
- PCL i primära molarer
- Pulpanekros i primär tand

21 november 2018 13

Tidig buckal emaljkarier




- Tandborstning med fluortandkräm 2 ggr/dag! A1
- Fluorlack B2







21 november 2018 14

Behandlingar




- Tidig buckal emaljkarier
- Buckal/approximal dentinkaries incisiver
- Buckal dentinkaries molarer
- Ocklusal emaljkarier
- Ocklusal dentinkaries
- Approximal emaljkarier
- Approximal dentinkaries
- PCL i primära molarer
- Pulpanekros i primär tand

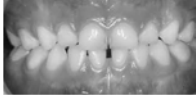
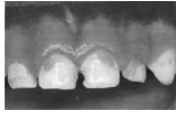


21 november 2018 15

Buckal/approximal dentinkaries incisiver



- Fluorlack B2
- ART C2
- Partiell excivering C2
- Fullständig excivering följt av fyllning med GPA C2
- Slipning C2

21 november 2018 16

Buckal/approximal dentinkaries incisiver




- Tandborstning med fluortandkräm 2 ggr/dag! A1

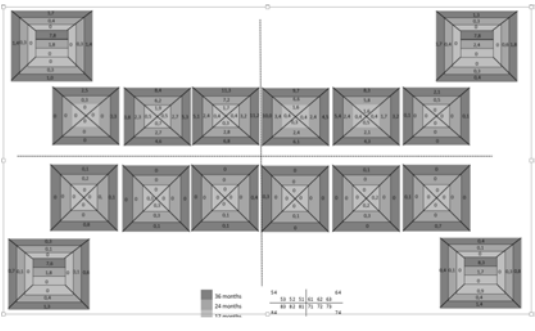




21 november 2018 17

Kariesprogression 1-3 år

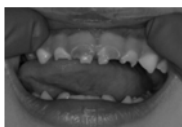



21 november 2018 18

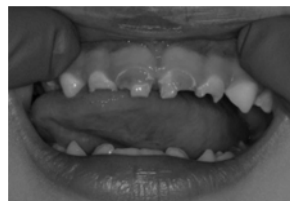Buckal/approximal dentinkaries incisiver

- Lisa 2.5 år, fullt frisk
- Ammad till 2.5 år (precis slutat)
- Nu välling på natten
- Choklad innan sänggående
- Tandborstning i perioder, nu 2 ggr/dag

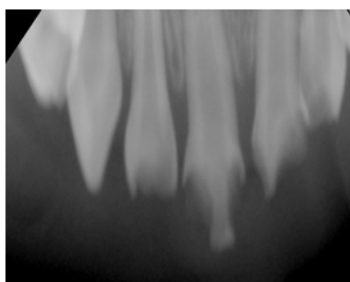


Tidig buckal/approximal emaljkarier incisiver

- Plack ök-front, övrigt rent
- Karies: Ök-front samt 74o, 84o

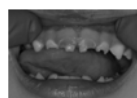

Akutisering

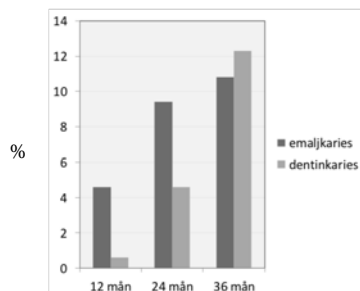


Tidig buckal/approximal emaljkarier incisiver

- Behandling ök-front:
 - Profylax
 - Tb 2 ggr/dag mha förälder



Andel barn med karies uppdelat på emalj och dentinkaries



Andersson.M, 2015

Behandlingar

- Tidig buckal emaljkaries
- Buckal/approximal dentinkaries incisiver
- Buckal dentinkaries molarer
- Ocklusal emaljkaries
- Ocklusal dentinkaries
- Approximal emaljkaries
- Approximal dentinkaries
- PCL i primära molarer
- Pulpanekros i primär tand

21 november 2018 24



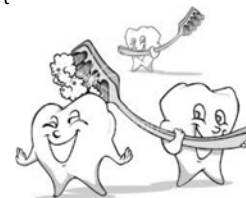Buckal dentinkaries molarer

- Tandborstning med fluortandkräm 2 ggr/dag! A1
- Fluorlack B2
- ART C2
- Partiell excavering C2
- Fullständig excavering följt av fyllning med GPA C2



Buckal dentinkaries

- Tandborstning!
- Laga vid djup kavitet



Behandlingar

- Tidig buckal emaljkarier
- Buckal/approximal dentinkaries incisiver
- Buckal dentinkaries molarer
- Ocklusal emaljkaries
- Ocklusal dentinkaries
- Approximal emaljkaries
- Approximal dentinkaries
- PCL i primära molarer
- Pulpanekros i primär tand

21 november 2018 27



Ocklusal emaljkaries

- Fluorlack C2
- Fissurförsegling C2
- Fissurblockering C1
- Fissurblockera vid djup fissur (sonderbart)



Behandlingar

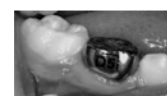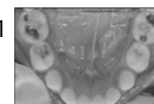
- Tidig buckal emaljkaries
- Buckal dentinkaries incisiver
- Buckal dentinkaries molarer
- Ocklusal emaljkaries
- Ocklusal dentinkaries
- Approximal emaljkaries
- Approximal dentinkaries
- PCL i primära molarer
- Pulpanekros i primär tand


21 november 2018 29



Ocklusal dentinkaries



- ART- Atraumatic Restorative Treatment C1
- Partiell excavering C1
- Stegvis excavering C2
- Fullständig excavering följt av fyllning med GPA C1
- Halls technique C2






ART - Definition

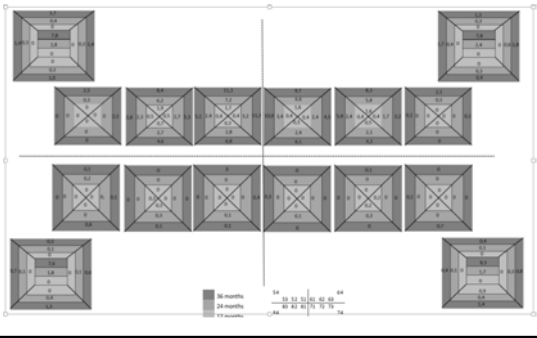
- ART - Atraumatic Restorative Treatment
- Atraumatisk excavering med:
 - Handexcavator
 - Power Drive + Carisolv
- Avlägsning av mjuk karies
- Restauration - Fyllning med GPA, puts





Koplan et al., 2009





Kariesprogression 1-3 år






Patientfall – ocklusal dentinkaries



- Lisa, 2.5 år
- God Kooperation, inskolning
- Dentinkaries: Ök-front, 74o, 84o







Patientfall – ocklusal dentinkaries

- 74o, 84o excavering med Power Drive, Carisolv, enligt ART
- Fyllning med gpa med kontroll av ocklusion
- Uppföljning profylax och ktr var 6e månad



ART - uppföljning





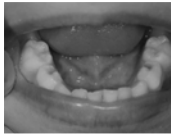
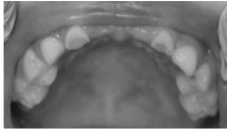



Figure 2. Radiograph of carious lesion in the primary mandibular right second molar (NSBS) at baseline (A) and 12-month follow-up period (B). A decrease of area of caries was observed at final evaluation.



Lisa– 5 år



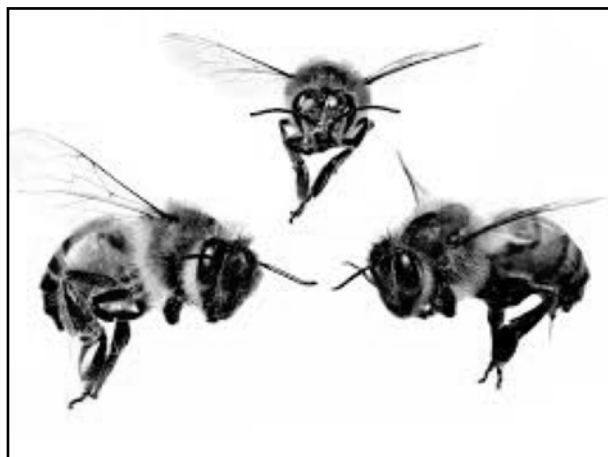
Bikupa

 Karolinska Institutet


- Skall vi rekommendera fyllningar enligt ART till alla barn under 3 år?





Narm Ekström 21 november 2018 37




ART - rekommendation

 Karolinska Institutet

- Låg evidens - C
- Beroende på omfattningen
- Uppföljning mycket viktig!
 - Profylax
- Alternativ till ART
 - Premedicinering + fyllning





Partiell excavering

 Karolinska Institutet

- Låg evidens - C
- Syfte: Undvika lesion
- Beroende på omfattningen
 - Djupet på kaviteten
 - Rent i periferin, karies kvar mot pulpan
 - Viktigt med tät fyllning
- Uppföljning viktig!
 - Profylax


Behandlingar

 Karolinska Institutet

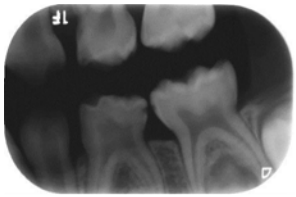
- Tidig buckal emaljkarier
- Buckal/approximal dentinkaries incisiver
- Buckal dentinkaries molarer
- Ocklusal emaljkarier
- Ocklusal dentinkaries
- Approximal emaljkarier
- Approximal dentinkaries
- PCL i primära molarer
- Pulpanekros i primär tand

21 november 2018 41

Approximal emaljkarier

 Karolinska Institutet

- Tandborstning A1
 - Med fluortandkräm



Behandlingar



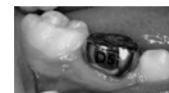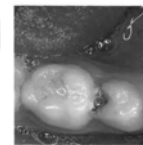
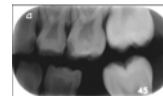
- Tidig bukkal emaljkarier
- Bukkal/approximal dentinkaries incisiver
- Bukkal dentinkaries molarer
- Ocklusal emaljkarier
- Ocklusal dentinkaries
- Approximal emaljkarier
- **Approximal dentinkaries**
- PCL i primära molarer
- Pulpanekros i primär tand

21 november 2018 43

Approximal dentinkaries



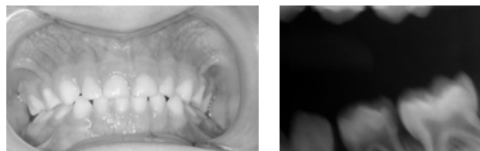
- ART C2
- Partiell excavering C1
- Stegvis excavering C2
- Fullständig excavering följt av fyllning med GPA C1
- Halls technique C2
- Slipning C3



Slipning



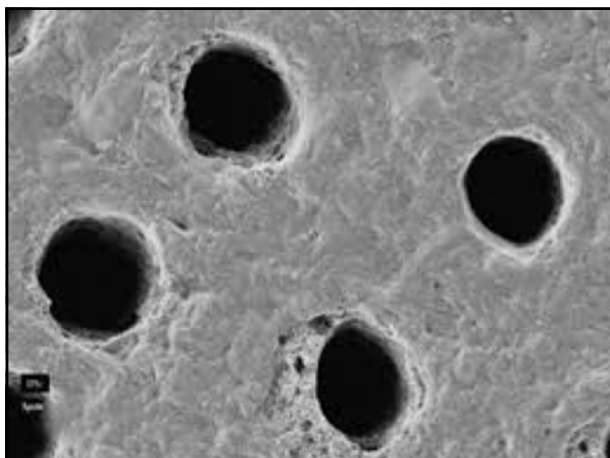
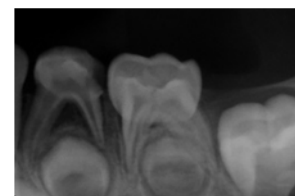
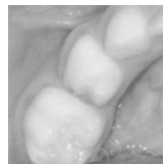
- Kalle, 4 år, klaffel
- Akutremiss: 74 slipad i augusti, värk, EO: svullen
- Fått Kävepenin, mår bättre, ingen värk
- Svullnad borta mha PC



Slipning



- Dentinkaries: 74d, öppen kavitet
- Diagnos: Apikal parodontit
- Ex 74 under premedicinering med midazolam
- Uppföljning



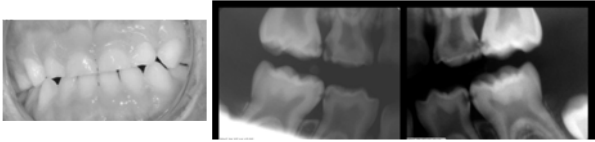
Partiell excavering



- Beroende på tand:
 - Fyror
 - Femmor
- Beroende på omfattningen
 - Djupet på kaviteten
 - Rent i periferin, karies kvar mot pulpan
 - Tät fyllning
- Uppföljning viktig!
 - Profylax

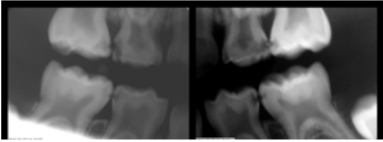
Approximal dentinkaries

- Anna, 5 år, förkylningsastma (Airomir)
- Anamnes: Tandborstning 2 gång/dag, mha förälder oftast
- Goda kostvanor, godis lördagar
- Dricker vatten på natten pga. muntorrhet



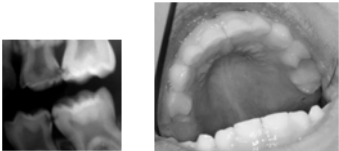
Approximal dentinkaries

- Food impaction ök - ont
- Dentinkaries: 55m, 54d, 64d, 65m, 74d, 75m, 84d, 85m
- Bw från januari
- Temporär fyllningar ök vid us-tillfället
- Inskolning



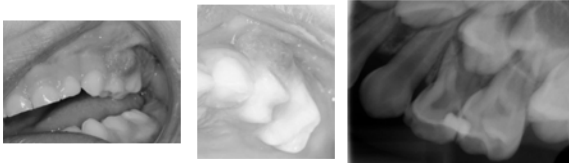
Approximal dentinkaries

- LA, excavering partiellt med hs och lv, pulpanära, rent i periferin
- Stor substansförlust
- Fyllning med gpa
- Värk upphörde efter fyllningar ök



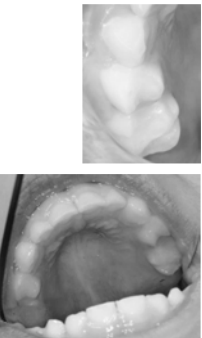
Approximal dentinkaries

- 64 fistel, apikal parodontit
- 64 ex under premed med midazolam



Approximal dentinkaries


- 54,55 u.a.
- Food impaction upphört, gingiva läkt
- Inget tecken på infektion
- Planerad terapi: lagn uk
- Uppföljning & profylax!



Behandlingar


- Tidig bukkal emaljkarier
- Bukkal/approximal dentinkaries incisiver
- Bukkal dentinkaries molarer
- Ocklusal emaljkarier
- Ocklusal dentinkaries
- Approximal emaljkarier
- Approximal dentinkaries
- PCL i primära molarer
- Pulpanekros i primär tand

21 november 2018 54



PCL i primära molarer


- Extraktion C1
- Partiell pulpotomi C1
- Kronpulpektomi C1
- Pulpaöverkappning C2



Behandlingar

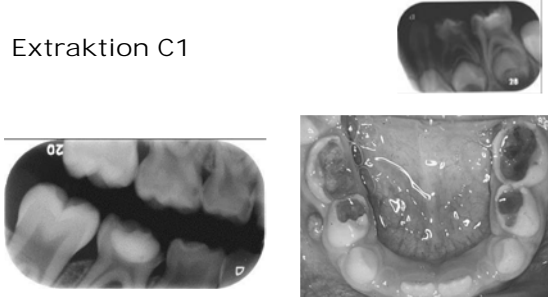
- Tidig buckal emaljkarier
- Buckal/approximal dentinkaries incisiver
- Buckal dentinkaries molarer
- Ocklusal emaljkarier
- Ocklusal dentinkaries
- Approximal emaljkarier
- Approximal dentinkaries
- PCL i primära molarer
- Pulpanekros i primär tand


21 november 2018 56



Pulpanekros i primär tand

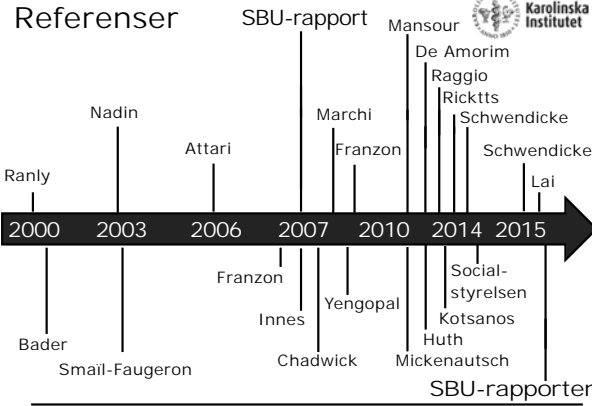
- Extraktion C1





Referenser

SBU-rapport






Kariesregistrering i framtiden?


- ICDAS - Vad är det?
- Varför ska vi använda ICDAS i framtiden?
- Webbsida med utbildning i kariesdiagnostik
 - ICDAS.org

<http://www.icdas.org>



ICDAS - kriterier

Sound	Early Stage Decay		Established Decay		Severe Decay	
Sound	First visual change in enamel	Distinct visual change in enamel	Localised enamel breakdown	Underlying dentine shadow	Distinct cavity with visible dentine	Extensive cavity within visible dentine
0	1	2	3	4	5	6



<http://www.icdas.org>

Best clinical practice guidance for management of early caries lesions in children and young adults: an EAPD policy document

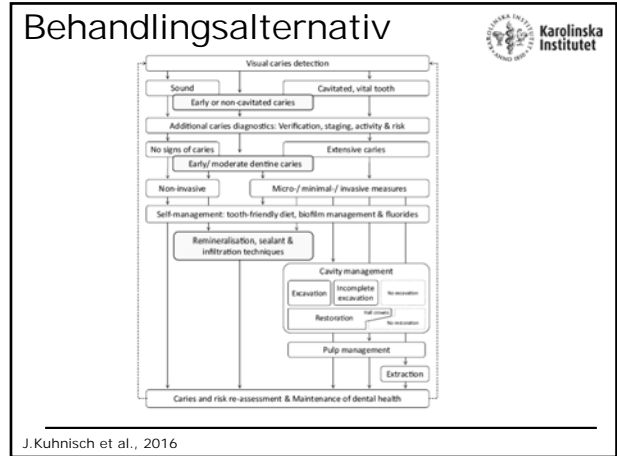
J. Kuhnisch¹, A. K. Vignery², F. Pavesi³, K. Thomsen⁴, C. van't Hof-Grootenboer⁵, A. Elvén⁶, M. Sjostrom Ekdahl⁷

Abstract Following the consensus review and consensus of the evidence, it was concluded that visual and radiographic caries detection should be utilized as a first diagnostic approach to locate, assess and monitor early carious lesions. The primary preventive strategy should be individualized based on patient and caries risk. The caries treatment exclusion strategy in caries risk assessment should be performed in a child's first dental visit, and management decided to be performed in a regular visit. It is widely accepted that non-restored caries lesions can be managed non-invasively in the majority of cases. The spectrum of measures includes a first caries-specific toothbrushing, daily and appropriate management of the healthy tissue and either the dental rehabilitation strategy of Remineralisation or Self-management. The detection and management of non-restored caries is an essential aspect of preventive dentistry. Therefore, the EAPD encourages and facilitates oral prevention and strategies to implement practices that can ultimately caries and improve individual and public dental health.

Keywords: Caries Detection, Diagnosis, Diagnostic methods, Prevention, Caries risk, Risk assessment, Caries treatment, Caries management

Introduction This best clinical practice guidance was agreed upon as a result of the scientific evidence and findings reported by the European Academy of Pediatric Dentistry in Brussels in May 2015. The consensus is based upon a comprehensive search of the literature that was additional and peer-reviewed by the steering committee (Pavesi and Thomsen 2015), van't Hof-Grootenboer and van't Hof-Grootenboer (2015).


J. Kuhnisch et al., 2016



Slutsatser

Flest C ← Kunskapslucka

- Stödja oss mot den forskning som finns!
- Konstaterat vad är best practice
- Stoppa kariesprogressionen
 - Behandla sjukdomen
- Vad ska vi inte göra?
 - Lika viktigt
- Stort behov av bra klinisk forskning!



Maria.Lundmark@ki.se

21 november 2018 65



Referenser

- **Molina M, Moberg V, Vignery A, Sjöström Ekdahl M, Thomsen K, Van't Hof-Grootenboer A** A systematic map of systematic reviews in pediatric dentistry—what do we really know? *PLoS One*. 2017;12(11):e0172093.
- SBU - Størens beredning för medicinsk utvärdering. Karies - diagnostik, riskbedömning och icke-invasiv behandling. En systematisk litteratursökning. December 2007
- Bader JD, Shugart DA, Bousso AJ (2001) A systematic review of selected caries prevention and management methods. *Community Dent Oral Epidemiol* 29: 399-411.
- Mickenautsch S, Yengopal V, Banerjee A (2010) Atraumatic restorative treatment versus amalgam restoration longevity: a systematic review. *Clin Oral Investig* 14: 233-240.
- **Schmidhake F, Pavesi F, Thomsen K, Thomsen K** Effects of using different criteria for caries removal: a systematic review and network meta-analysis. *J Dent*. 2015 Jan;43(1):1-15.
- De Assunção, da Costa Gde F, Borges BC. Systematic review of noninvasive treatments to arrest dentin non-cavitated caries lesions. *World J Clin Cases* 2014;6:2137-41. (Peer-reviewed article)
- **Schmidhake F, Pavesi F, Pavesi F, Pavesi F, Pavesi F, Pavesi F** Treating pit-and-fissure caries: a systematic review and network meta-analysis. *J Dent Res*. 2015 Apr;94(4):522-33 (Peer-reviewed article)
- Material för fyllningar och fissuröppningar inom barn- och ungdomstandvården – En systematik översikt. www.socialstyrelsen.se, januari 2014
- **De Amorim RCF, Louf SC, Pinheiro JE** Survival of atraumatic restorative treatment (ART) sealants and restorations: a meta-analysis. *Clin Oral Invest*. 2012 Apr;16(2):429-34.
- **Green DP, Green DP, Green DP, Green DP, Green DP, Green DP, Green DP, Green DP, Green DP, Green DP** Atraumatic restorative treatment an option for restoring occlusoproximal caries lesions in primary teeth? A systematic review and meta-analysis. *PLoS One*. 2013 Nov;8(11):e82433.
- Ricketts D, Lamont T, Innes NP, Kidd E, Clarkson JE (2013) Operative caries management in adults and children. *Cochrane Database Syst Rev*. 2013 Mar 28
- **Schmidhake F, Pavesi F, Pavesi F** Incomplete caries removal: a systematic review and meta-analysis. *J Dent Res*. 2013 Apr;92(4):306-14.
- **Lai CP, Lora-Curi G, Cecchi F, Parenti MG, Iannetti P, Alamberti LL, Casasco CA** Comparison of Carisolv system vs traditional rotating instruments for caries removal in the primary dentition: A systematic review and meta-analysis. *Acta Odontol Scand*. 2015 Mar 14:1-12.

Referenser



- James NP, Rickets DN, Evans DJ (2007) Prefabricated metal crowns for decayed primary molar teeth. *Cochrane Database Syst Rev*. 2007 Jan 24
- Yengopal V, Hanraek SY, Patel N, Siegfried N (2009) Dental fillings for the treatment of caries in the primary dentition. *Cochrane Database Syst Rev*: CD004483.
- [Amini N, Babiker JF](#). Restoration of primary teeth with crowns: a systematic review of the literature. *Eur Arch Paediatr Dent*. 2006 Jun;7(2):58-62; discussion 63.
- [Oshiro K, Hsu L, Yamaji H](#). Restoration of class II cavities in primary molar teeth with conventional and resin modified glass ionomer cements: a systematic review of the literature. *International Dental Journal*. 2007 Mar;8(1):14-21.
- [Kotomasa N, Arasonathis KN, Adhikari A, Meneses G](#). Direct pulp capping of carious primary molars. A specialty practice based study. *J Clin Pediatr Dent*. 2014 Summer;38(4):507-12.
- [Mirchi H, Firooz AM, Akbari H, Boroumand CP, Arastu EB](#). Analysis of primary tooth dentin after indirect pulp capping. *J Dent Child (Chic)*. 2008 Sep-Dec;75(3):296-300.
- [Guzman R, Castorena J, Dominguez Garcia-Godoy E, Malo M, de Arango EB](#). Clinical and radiographic evaluation of indirect pulp treatment in primary molars: 36 months follow-up. [doi:10.1016/j.jdent.2012.05.019](#)
- [Guzman R, Gomez M, Hiraldo C, Boroumand CP, Arastu EB](#). Dentin rehardening after indirect pulp treatment in primary teeth. *J Dent Child (Chic)*. 2009 Sep-Dec;76(3):238-8.
- [Rush DMC, Garcia-Godoy E](#). Current and potential pulp therapies for primary and young permanent teeth. *J Dent*. 2000 Mar;28(3):153-61.
- [Hahn HC, Hahn AJ, Khouri N, Wolf P, Wu N, Hinkel B, Puschel E](#). *Long-term effectiveness of four restorative techniques: a non-randomized controlled trial*. 2012 Aug;19(1):143-50.
- Nadin G, Geel BR, Yeung CA, Ghemly AM (2003) Pulp treatment for extensive decay in primary teeth. *Cochrane Database Syst Rev*: CD003220. PMID: 12535462
- [Smith-Farrington V, Curran F, Durrant P, Miller-Bolla M, Glenn AM, Finn-Chubbuck H](#). Pulp treatment for extensive decay in primary teeth. 2003;(1)
- [Minnear O'Keefe N, Binesand M](#). Reasons for extractions, and treatment preceding caries related extractions in 3-8 year-old children. *Eur Arch Paediatr Dent*. 2010 Jun;11(3):123-30.
- [J. Karimachi et al](#). Best clinical practice guidance for management of early caries lesions in children and young adults: an EAPD policy document. *Eur Arch Paediatr Dent*. 2016;17(2):19.



Caries, A clinical and microbiological comparative study of deep carious lesion treatment in deciduous and young permanent molars, *Clin Oral Investig*, 2008.pdf